

Displacement pattern of the anterior segment using antero-posterior lingual retractor combined with a palatal plate

Kyung-Won Seo^a
Soon-Yong Kwon^a
Kyung A Kim^a
Ki-Ho Park^a
Seong-Hun Kim^a
Hyo-Won Ahn^a
Gerald Nelson^b

^aDepartment of Orthodontics, School of Dentistry, Kyung Hee University, Seoul, Korea

^bDivision of Orthodontics, Department of Orofacial Science, University of California San Francisco, San Francisco, CA, USA

Objective: To evaluate and compare the effects of two appliances on the *en masse* retraction of the anterior teeth anchored by temporary skeletal anchorage devices (TSADs). **Methods:** The sample comprised 46 nongrowing hyperdivergent adult patients who planned to undergo upper first premolar extraction using lingual retractors. They were divided into three groups, based on the lingual appliance used: the C-lingual retractor (CLR) group (group 1, n = 16) and two antero-posterior lingual retractor (APLR) groups (n = 30, groups 2 and 3). The APLR group was divided by the posterior tube angulation; posterior tube parallel to the occlusal plane (group 2, n = 15) and distally tipped tube (group 3, n = 15). A retrospective clinical investigation of the skeletal, dental, and soft tissue relationships was performed using lateral cephalometric radiographs obtained pretreatment and post *en masse* retraction of the anterior teeth. **Results:** All groups achieved significant incisor and canine retraction. The upper posterior teeth did not drift significantly during the retraction period. The APLR group had less angulation change in the anterior dentition, compared to the CLR group. By changing the tube angulation in the APLR, the intrusive force significantly increased in the distally tipped tube of group 3 patients and remarkably reduced the occlusal plane angle. **Conclusions:** Compared to the CLR, the APLR provides better anterior torque control and canine tipping while achieving bodily translation. Furthermore, changing the tube angulation will affect the amount of incisor intrusion, even in patients with similar palatal vault depth, without the need for additional TSADs. [Korean J Orthod 2015;45(6):289-298]

Key words: Lingual orthodontics, C-lingual retractor, Mini-implant, Intrusion

Received May 14, 2015; Revised July 14, 2015; Accepted July 15, 2015.

Corresponding author: Hyo-Won Ahn.

Assistant Professor, Department of Orthodontics, School of Dentistry, Kyung Hee University, 26 Kyungheedaero, Dongdaemun-gu, Seoul 02447, Korea.

Tel +82-958-9392 **e-mail** acehyohyo@hanmail.net

*This work was supported by the National Research Foundation of Korea (NRF) and funded by the Korean government (MEST; No. 2012R1A5A2051388).

The authors report no commercial, proprietary, or financial interest in the products or companies described in this article.

© 2015 The Korean Association of Orthodontists.

This is an Open Access article distributed under the terms of the Creative Commons Attribution Non-Commercial License (<http://creativecommons.org/licenses/by-nc/4.0>) which permits unrestricted non-commercial use, distribution, and reproduction in any medium, provided the original work is properly cited.

INTRODUCTION

For patients with bimaxillary or bidentoalveolar protrusion that requires the extraction of premolars, retraction with conventional fixed lingual appliances sometimes induces adverse effects such as failure of torque expression or the extrusion of the anterior teeth. A good outcome could require using additional temporary skeletal anchorage devices (TSADs) or adding labial appliances. This waste of treatment time and the challenge of good control of the teeth roots have led us to propose splinting the anterior and posterior segments.¹

Retraction of the anterior teeth as a lingually splinted unit with forces applied from the splint to a palatal TSAD has a biomechanical advantage. If the retraction lever arms are of the correct length, the force vector will pass through the center of resistance.^{2,3} A C-lingual retractor (CLR) splints the six maxillary anterior teeth and retracts them by using palatal TSADs without posterior bonding (Figure 1A–1C).⁴ This eliminates adverse effects in lingual bracket-archwire systems such as torque loss or distalization of the buccal teeth resulting from friction in the brackets and tubes.^{5–8} However, other undesirable movements of the anterior segment can occur because

the lingual splint is retracted by flexible traction modules.⁵ If the malocclusion requires intrusion of the anterior segment and retraction, additional TSADs would be required. As reported earlier, a CLR provides bodily translation of the anterior segment; however, the canines can sometimes tip excessively.^{5,7} To avoid these complications, the canine segmental wire has to be sectioned to allow individual control of the teeth.^{6,7}

The antero-posterior lingual retractor (APLR) is a modified design in which the posterior segment sliding mechanics is added to the CLR (Figure 1D–1F).^{9,10} This posterior sliding feature is expected to control canine movement and direct the translation of the anterior segment. The posterior teeth are splinted with buccal meshes to minimize any movement of these teeth. On the palatal surface, a tube on each side accepts a guide wire that connects the splinted anterior segments to the posterior segments. The guide wires direct the anterior segment retraction course and prevent unwanted canine movement.¹⁰

A key strategy of lingual biocreative therapy is multi-purpose biomechanics.^{7–10} With the APLR, the posterior teeth are used for anchorage control, vector control, and vertical control. The guide bar and the posterior teeth can be intruded together by friction within the appliance.^{9,10}

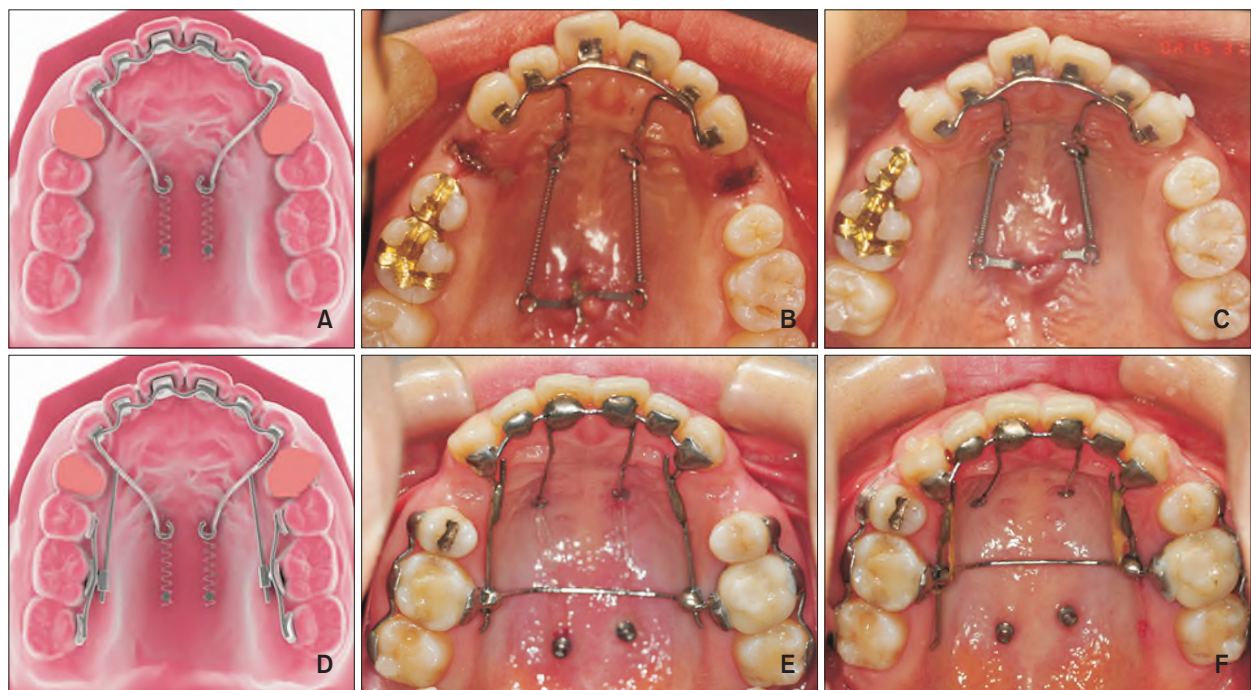


Figure 1. The occlusal diagrams and intraoral photos. A–C, The C-lingual retractor and D–F, the antero-posterior lingual retractor. A, No posterior orthodontic appliance is in place. B, Pretreatment and C, Post *en masse* retraction by the C-lingual retractor. D–F, The posterior teeth are splinted buccally and the guide bar and posterior tubes are in place. E, Pretreatment and F, Post *en masse* retraction by the antero-posterior lingual retractor.

Friction occurs at the junction of the guide wires and the tubes as the retraction continues. It works by binding the guide wires and tube as one unit. The posterior buccal segments then intrude because the retraction force vector originates from the palatal TSADs. The resulting orthodontic tooth movement depends on the retraction arm length and the tube angulation. The tubes can be placed parallel to the occlusal plane or distally tipped.

We hypothesized that the amount of angulation during retraction would generate a difference in the amount of intrusion of the anterior segment. Therefore, the aim of this study was to compare the clinical outcomes of *en masse* anterior dental retraction using the APLR or the CLR after extracting the premolars with a focus on the effects on the intrusion of the anterior and posterior teeth and anterior torque control. We also analyzed the difference in tooth movements caused by the APLR when the posterior tube angulation is changed.

MATERIALS AND METHODS

Samples

Retrospective data were obtained from pretreatment and postretraction lateral cephalometric radiographs of 46 patients (40 females and six males) who met the following criteria: the patient had skeletal Class I or

Table 1. The patient demographic data of all three groups

	Group 1	Group 2	Group 3
Number	16	15	15
Sex (male/female)	2/14	3/12	1/14
Mean age (yr)	23.6	26.8	22.6
Mean retraction period (mo)	11.8	11.2	13.6

Group 1, C-lingual retractor; group 2, antero-posterior lingual retractor with parallel tube; group 3, antero-posterior lingual retractor with distally tipped tube.

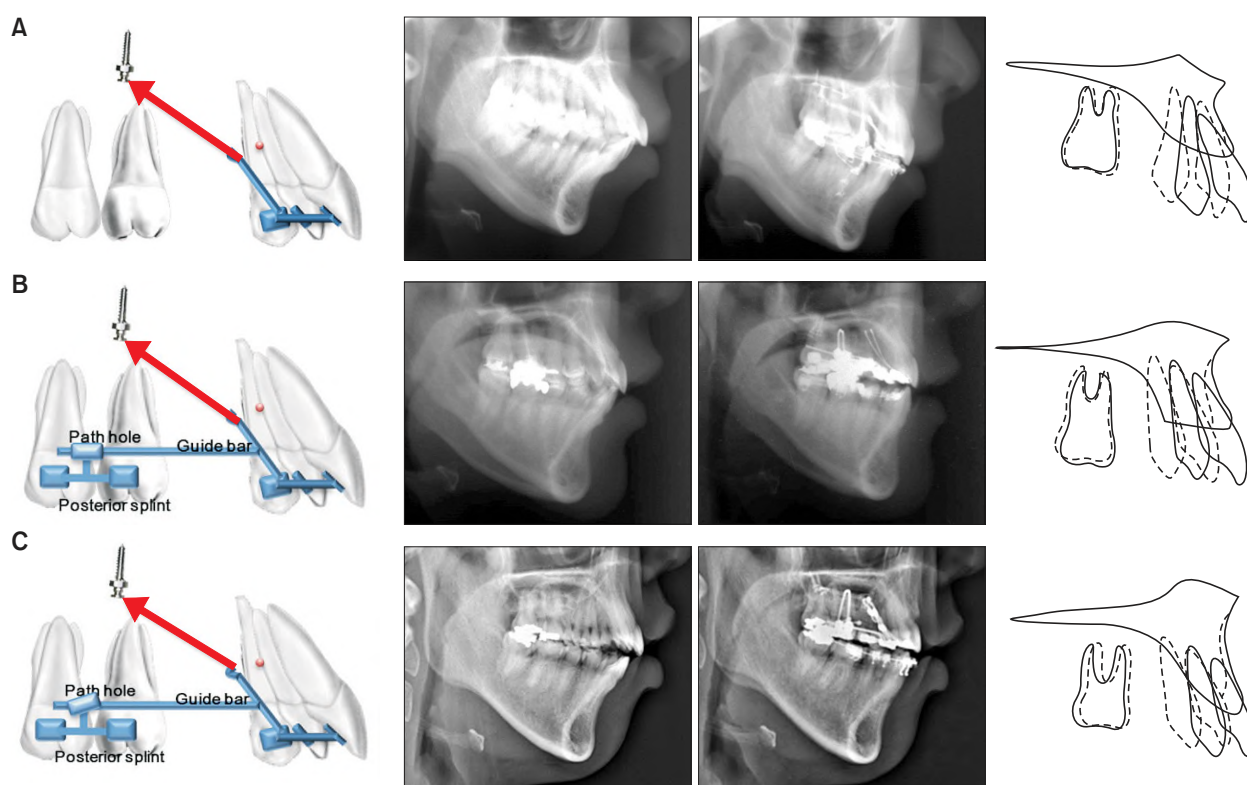


Figure 2. Schematic illustrations of the appliance in each group (lateral view; left column); lateral cephalograms at pretreatment and post *en masse* retraction (middle column); and maxillary superimposition (right column). **A**, The C-lingual retractor group (i.e., group 1) had clockwise rotation of the anterior segment during retraction. **B**, The antero-posterior lingual retractor with parallel tube group (i.e., group 2) had intrusion of the anterior segment with less clockwise moment. **C**, The antero-posterior lingual retractor with distally tipped tube group (i.e., group 3) had the greatest amount of intrusion on the anterior segment. Extrusion of the posterior segments did not occur in group 2 or group 3.

mild skeletal Class II malocclusion (ANB angle, 2° – 6°); the individual was a nongrowing hyperdivergent patient (SN-MP angle, $>35^{\circ}$) with no or mild anterior crowding; and the patient planned to undergo extraction of the upper first premolars. Among these 46 patients, two groups were formed, based on the type of lingual appliance used: the CLR group (group 1, $n = 16$) and the APLR group (groups 2 and 3, $n = 30$ patients). The APLR group was further divided into two groups; group 2 ($n = 15$) had parallel posterior tubes to the occlusal plane and group 3 ($n = 15$) had a distally tipped tube close to the gingiva in the distal aspect of tube. In group 3, the posterior tube had two points of contact with the guide wire. The exclusion criteria were the following: missing or malformed teeth, tooth size anomalies, and moderate or severe crowding. The institutional review board (IRB) at School of Dentistry, Kyung Hee University reviewed this preliminary report and associated data (IRB approval no., KHD IRB1407-1). Table 1 shows the demographic data of each group such as the number of patients, sex distribution, age at the initiation of treatment, and the duration of active retraction period.

Anterior retraction using a CLR or APLR

The CLR was fabricated with a 0.036-inch stainless steel wire that splinted lingually bonded meshes on the six anterior teeth as one unit (Figure 2A). It included a retractor arm length that was designed to steer the

force vector through the center of resistance during the retraction.¹¹ The C-plates were used as the sole source of anchorage. There was no posterior appliance. The reference for the detailed treatment method has been explained in previous articles.⁵⁻⁷

The APLR was composed of a 0.036-inch stainless steel wire that was soldered to lingual mesh pads that were bonded to the anterior segment in one unit. It included sliding guide wires that connect the anterior and posterior segments. The retraction forces were applied from miniscrews placed at the paramedian area of the posterior palate (Jin Biomed Co., Bucheon, Korea). The retraction arms were soldered to the anterior segment between the lateral incisors and canines. The locations

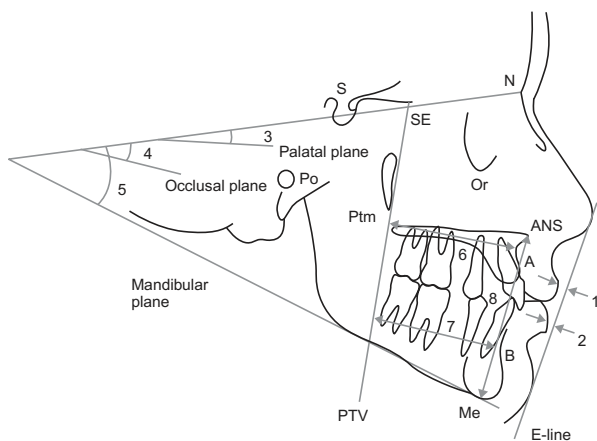


Figure 3. Soft tissue and skeletal cephalometric analysis. 1, The upper lip to the E line; 2, the lower lip to the E line; 3, the sella-nasion to the palatal plane angle (SN-PP); 4, the SN-anatomic occlusal plane angle (SN-Occ); 5, the SN to the mandibular plane angle (SN-Mn); 6, the distance between the pterygoid vertical plane and point A (PTV-A); 7, the distance between the pterygoid vertical plane and point B (PTV-B); and 8, the lower anterior face height (LAFH; ANS-Me). Refer Table 2 for definitions of the landmarks.

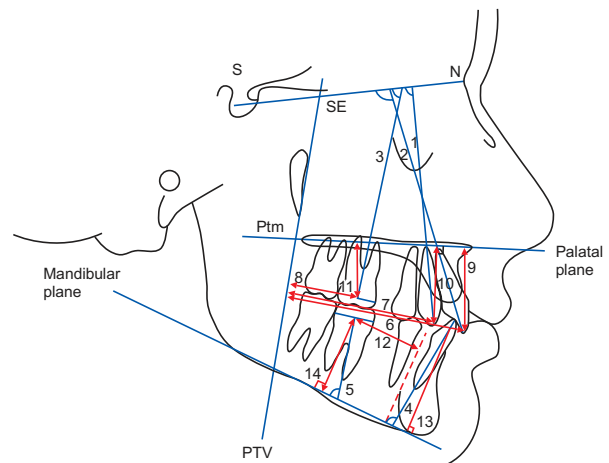


Figure 4. Dental cephalometric analysis, based on the angular and linear measurements. 1, The SN to the maxillary canine angle (SN-C); 2, the SN to the maxillary incisor angle (SN-U1); 3, the SN to the maxillary first molar angle (SN-U6); 4, the mandibular plane to mandibular incisor angle (MP-L1); 5, the mandibular plane to mandibular first molar angle (MP-L6); 6, the distance between the pterygoid vertical plane and the maxillary incisor tip (PTV-U1); 7, the distance between the pterygoid vertical plane and the maxillary canine tip (PTV-C); 8, the distance between the pterygoid vertical plane and the maxillary first molar centroid (PTV-U6); 9, the distance between the palatal plane and the maxillary incisor tip (PP-U1); 10, the distance between the palatal plane and the maxillary canine tip (PP-C); 11, the distance between the palatal plane and the maxillary first molar centroid (PP-U6); 12, the distance between the mandibular lingual cortex and the mandibular first molar centroid (LC-L6); 13, the distance between the mandibular plane and the mandibular incisor tip (MP-L1v); and 14, the distance between the mandibular plane and the mandibular first molar centroid (MP-L6v). Refer Table 2 for definitions of the landmarks.

of the retraction arms were designed, based on a cast of the patient, to pass through the center of resistance of the six anterior teeth. The 0.036-inch stainless steel guide wires were soldered to the splinted anterior segment distal to the canines. They connected the anterior segment to the posterior segment by passing through the posterior tubes. A single tube on each side is extended apically from the lingual mesh pad that is bonded to the first molars. The guide wires pass through the tube passively to prevent friction during retraction. The play in the tube was 0.1 mm (Figure 2B and 2C).

In the initial lateral cephalographs, the palatal vault height was measured from the occlusal plane to the palate at the mesial aspect of the first molar. The average palatal vault height was 21.1 mm: group 1, 21.0 mm; group 2, 20.8 mm; and group 3, 21.5 mm. The lever arm length was similar for all groups at approximately 20 mm. The position of the plate or screws was controlled to apply similar force vectors. The elastic power chains which produced a force of approximately 200 g per side (total 400 g), were connected between the TSADs and the soldered lever arms. Patients visited the clinic every four weeks during the anterior retraction period. The retraction of the lower anterior dentition was accomplished by conventional methods. No intermaxillary elastics were applied during the retraction

period. After space closure was achieved, the lingual retractor was removed and a conventional orthodontic bracket was bonded for further leveling and alignment concomitant with the finishing procedure.

To focus on the treatment effects on the anterior and posterior teeth, cephalograms were analyzed by comparing the images of the initial status (T1) and the end of active retraction period (T2). Soft tissue, skeletal, and dental measurements have been explained in previous studies.^{7,11,12} These measurements are shown in Figures 3 and 4. The definitions of cephalometric landmarks used in this study are shown in Table 2.

Statistical analysis

The mean and standard deviation of the 22 variables were calculated. The Shapiro-Wilk test for normality showed that all variables were normally distributed. The Levene's test showed homogeneity of all variables. Pre-treatment to postretraction changes for each variable were analyzed with a paired *t*-test. One-way analysis of variance (ANOVA) was performed with Scheffe's multiple comparison to evaluate the differences between the three groups. To evaluate tracing and measurement errors, the experimental procedures of the records of 46 patients (92 sets of cephalograms) were repeated 3 weeks later.

Table 2. Definitions of cephalometric landmarks used in this study

Landmark	Abbreviation	Definition
Upper lip	UL	The point indicating the mucocutaneous border of the upper lip, usually the most anterior point of the upper lip
Lower lip	LL	The median point on the lower margin of the lower membranous lip
Sella	S	Centre of the sella turcica
Nasion	N	The most anterior point on the frontonasal suture in the facial midline
Anterior nasal spine	ANS	The most anterior point of the anterior nasal spine of the maxilla on the mid-sagittal plane
Posterior nasal spine	PNS	The most posterior point on the sagittal plane of the bony hard palate
Menton	Me	The most inferior point in the symphysis
Point A	A	The deepest bony point on the contour of the premaxilla below ANS
Point B	B	The deepest bony point on the contour of the mandible above the pogonion
Pterygomaxillary	Ptm	The most inferior point of intersection of the images of the anterior surface of the pterygoid process of the sphenoid bone and the posterior margin of the maxilla
Maxillary incisor tip	U1	The incisal edge of the maxillary central incisor
Maxillary canine tip	C	The cusp tip of the maxillary canine
Maxillary first molar centroid	U6	The midpoint of the crown width of the maxillary first molar
Mandibular lingual cortex	LC	The line tangential to the posterior margin of symphysis and at right angles to the mandibular plane
Mandibular first molar centroid	L6	The midpoint of the crown width of the mandibular first molar
Mandibular incisor tip	L1	The incisal edge of the mandibular central incisor

Table 3. Comparisons of the cephalometric measurements before treatment and after *en masse* retraction

Variable	Group 1			Group 2			Group 3		
	T1	T2	p-value	T1	T2	p-value	T1	T2	p-value
Soft tissue									
Upper lip to E line	4.08 ± 2.18	1.10 ± 2.34	0.0000***	3.11 ± 2.07	1.05 ± 2.06	0.0001***	3.20 ± 2.51	1.53 ± 2.04	0.0000***
Lower lip to E line	7.03 ± 3.10	3.01 ± 2.93	0.0000***	4.71 ± 2.40	2.57 ± 2.90	0.0040**	5.62 ± 2.57	2.87 ± 2.38	0.0000***
Skeletal									
SN-PP	10.51 ± 3.48	10.49 ± 3.50	0.8937	8.69 ± 4.05	8.72 ± 3.88	0.7712	10.47 ± 2.01	10.54 ± 1.87	0.5655
SN-Occ	21.32 ± 4.22	21.00 ± 5.00	0.6006	20.51 ± 4.32	19.87 ± 4.99	0.3575	23.13 ± 5.60	20.11 ± 6.48	0.0004***
SN-Mn	42.69 ± 5.51	42.95 ± 5.13	0.4739	41.21 ± 6.91	41.06 ± 6.96	0.6515	40.49 ± 8.03	40.09 ± 8.27	0.3213
PTV-A	53.45 ± 4.00	51.13 ± 3.37	0.0013**	50.37 ± 3.41	49.15 ± 3.41	0.0014**	51.27 ± 2.71	49.69 ± 3.71	0.0381*
PTV-B	47.09 ± 6.19	46.52 ± 6.41	0.2689	41.09 ± 7.02	40.03 ± 6.28	0.0477*	42.41 ± 5.79	42.42 ± 6.05	0.9840
ANS-Me	76.82 ± 6.15	76.91 ± 5.40	0.9112	79.87 ± 3.75	80.61 ± 4.91	0.2043	79.63 ± 5.58	78.77 ± 4.93	0.0324*
Dental angular									
SN-U1	106.66 ± 6.60	96.01 ± 7.56	0.0000***	107.14 ± 5.68	102.80 ± 5.39	0.0112**	104.26 ± 4.62	103.01 ± 5.95	0.0933
SN-C	89.09 ± 5.82	81.21 ± 8.51	0.0002***	92.51 ± 6.45	90.22 ± 6.83	0.1481	90.41 ± 5.27	88.05 ± 7.64	0.0245*
SN-U6	70.99 ± 4.22	71.70 ± 4.54	0.3497	72.43 ± 5.97	73.63 ± 7.28	0.4829	74.22 ± 6.37	71.87 ± 6.68	0.2251
MP-L1	98.51 ± 7.83	85.52 ± 9.03	0.0000***	98.22 ± 7.01	89.49 ± 7.79	0.0007***	100.48 ± 6.34	92.33 ± 9.53	0.0003***
MP-L6	76.53 ± 8.33	74.55 ± 6.06	0.2526	79.52 ± 6.45	74.68 ± 5.33	0.0051**	79.31 ± 4.02	76.59 ± 6.05	0.0590
Dental linear									
PTV-U1	63.41 ± 5.09	56.35 ± 5.13	0.0000***	59.49 ± 5.43	53.71 ± 4.63	0.0000***	60.23 ± 3.61	54.61 ± 3.96	0.0000***
PTV-C	50.63 ± 4.00	44.39 ± 4.32	0.0000***	48.29 ± 4.60	42.82 ± 4.25	0.0000***	48.47 ± 3.44	42.96 ± 3.65	0.0000***
PTV-U6	24.41 ± 3.27	24.47 ± 2.96	0.8709	21.47 ± 3.54	21.71 ± 3.13	0.4237	22.07 ± 2.67	22.58 ± 2.82	0.1920
PP-U1	32.78 ± 3.11	31.60 ± 3.06	0.0353*	34.54 ± 1.95	33.07 ± 2.11	0.0001***	34.75 ± 3.04	30.99 ± 2.71	0.0000***
PP-C	31.67 ± 2.15	30.26 ± 2.72	0.0009***	33.62 ± 1.90	31.54 ± 1.73	0.0000***	33.35 ± 3.22	29.92 ± 2.72	0.0000***
PP-U6	21.53 ± 3.05	21.40 ± 2.52	0.7446	23.89 ± 1.89	23.51 ± 2.29	0.2265	23.12 ± 3.29	22.73 ± 3.22	0.1157
LC-L6	19.80 ± 3.46	19.09 ± 3.33	0.1569	19.66 ± 3.58	18.47 ± 3.86	0.0030**	19.85 ± 3.11	18.11 ± 3.04	0.0003**
MP-L1v	48.12 ± 3.50	46.08 ± 2.45	0.0098	49.57 ± 3.35	48.79 ± 3.14	0.0269*	48.95 ± 2.39	47.91 ± 3.15	0.0045**
MP-L6v	32.08 ± 2.60	32.11 ± 2.62	0.9399	35.15 ± 4.14	35.39 ± 4.08	0.4682	35.68 ± 2.74	35.82 ± 2.94	0.5845

Values are presented as mean ± standard deviation.

Group 1, The C-lingual retractor group; group 2, the antero-posterior lingual retractor with parallel tube group; group 3, the antero-posterior lingual retractor with distally tipped tube group; T1, before treatment; T2, after *en masse* retraction.

The cephalometric landmarks for Tables 3 and 4 are the following: ANS-Me, lower anterior face height; IC-L6, mandibular lingual cortex to mandibular first molar centroid distance; MP-L1, mandibular plane to mandibular incisor angle; MP-L1v, mandibular plane to mandibular incisor tip distance; MP-L6, mandibular plane to mandibular first molar angle; MP-L6v, mandibular plane to mandibular first molar centroid distance; PP-C, palatal plane to maxillary canine tip distance; PP-U1, palatal plane to maxillary incisor tip distance; PP-U6, palatal plane to maxillary first molar centroid distance; PTV-A, pterygoid vertical plane to A point distance; PTV-B, pterygoid vertical plane to B point distance; PTV-C, pterygoid vertical plane to maxillary canine tip distance; PTV-U1, pterygoid vertical plane to maxillary incisor tip distance; PTV-U6, pterygoid vertical plane to maxillary first molar centroid distance; SN-PP, SN to palatal plane angle; SN-Mn, SN to mandibular plane angle; SN-Occ, SN-anatomic occlusal plane angle; SN-U1, SN to maxillary incisor angle; SN-U6, SN to maxillary first molar angle.

* $p < 0.05$, ** $p < 0.01$, and *** $p < 0.001$, based on the paired *t*-test.

Refer Table 2 for definitions of the landmarks.

RESULTS

The results of the Pearson correlation coefficient, which was used to compare the second measurement to the first measurement for each variable, were greater than 0.97 at 95% confidence. Therefore, the average value of each variable was used.

The mean retraction period of each group was 11.8 months for group 1, 11.2 months for group 2, and 13.6 months for group 3. The soft tissue, skeletal, and dental pretreatment and postretraction measurements of each group are compared in Table 3.

Based on pretreatment and post *en masse* retraction statistics, all groups showed significant soft tissue changes in which the upper and lower lips both moved posteriorly (all, $p < 0.001$; Table 3). A notable point remodeling occurred skeletally in all groups ($p < 0.01$ in groups 1 and 2; $p < 0.05$ in group 3). Group 3 had a significant decrease in the sella-nasion (SN) to occlusal plane angle ($p < 0.001$, Table 3) and lower anterior facial height ($p < 0.05$, Table 3). The SN to occlusal plane angle of group 3 showed a significant reduction of 3.02° , compared to the two other groups (group 1, -0.32° ; group 2, -0.61° ; Table 4).

All groups had significant anterior retraction with a reduction in the pterygoid vertical plane (PTV) to the maxillary central incisor tip or canine distance (PTV-U1 and PTV-C; for all, $p < 0.001$; Table 3). The lingual tipping of the maxillary central incisors was apparent in group 1 and group 2 (SN to U1 changes: -10.65° in group 1, $p < 0.001$; and -4.34° in group 2, $p < 0.01$). Group 1 had significant torque loss of the maxillary anterior teeth, compared to the other groups ($p < 0.001$, Table 4). All three groups showed intrusion of the central incisors ($p < 0.05$ in group 1, $p < 0.001$ in groups 2 and 3; Table 3). Group 3 had the most remarkable changes ($p < 0.001$; Table 4).

The canines had a retraction pattern similar to that of the central incisors. The angular change was significant in group 1, compared to the other groups (SN to C changes: -7.88° in group 1, -2.29° in group 2, and -2.35° in group 3; $p < 0.05$; Table 4). All groups achieved significant intrusion of the canines (for all, $p < 0.001$; Table 3) with greater intrusion in group 3 ($p < 0.01$; Table 4). The maxillary first molar angulation or position showed no significant statistical differences among the three groups.

DISCUSSION

During retraction with the CLR, canine crowns tipped excessively and required additional torque control after retraction. When this adverse effect was corrected in subsequent treatment, root end resorption was no-

ted.¹³ The root resorption is more evident on root apices that had encountered or perforated the cortical plate.¹⁴ Careful control of canine root positions during retraction can mitigate such adverse effects. The three-dimensional control of the anterior teeth movement can be challenging, depending on the morphology of the palatal vault of the patient.¹⁵ To cope with this when using CLR treatment or lingual braces treatment, a clinician will resort to additional TSADs or other complex biomechanics. The following components were added to the APLR to simplify the biomechanics, reduce undesired movement, and direct the pathway of the retraction:

1. Posterior guiding wires to control and direct the retraction vectors
2. Different posterior tube angulations to affect the amount of anterior intrusion
3. Buccal mesh pads for rigid posterior anchorage control
4. The use of only one or two palatal TSADs for whole tooth movement

The posterior tubes and guide arms added to the APLR control the retraction in three dimensions. Angulation of the guide tube affects intrusion, the guide arms control the sagittal retraction, and the addition of a transpalatal arch controls the transverse dimension. In both APLR groups, bodily translation or controlled tipping of the anterior teeth occurred. The undesirable adverse effects associated with CLR or lingual brackets and archwires were not evident.

Adjusting the angulation of the posterior tube can regulate the amount of anterior intrusion. In the present study, we found that a change in angulation of the posterior tube in APLR produced a significant difference in the amount of anterior teeth intrusion while the bodily retraction of the anterior segment remained well controlled. In group 2, tube angulation parallel to the occlusal plane resulted in bodily translation of anterior segment without much change in the SN to central incisors angle or the canine axis. Intrusion increased when the tubes were tipped coronally at the distal end, as in group 3. Altering the tube angulation can be an effective treatment method for treating patients with excessive gingival display (i.e., patients with more than 3 mm gingival display). The APLR groups (i.e., groups 2 and 3) had the same lever arm length. The change in the tube angulation increased the intrusion. group 3 (i.e., the distally tipped tube group) achieved more intrusion without increased crown tipping.

The clockwise rotation of the anterior segment can be minimized by the resistance generated between the path hole and the heavy guide wire. The distally tipped tube

Table 4. Comparisons of the changes in the lateral cephalometric variables between the three groups

Variable	Group 1	Group 2	Group 3	Significance	Multiple comparison (group No)
Soft tissue					
Upper lip to E line	-2.98 ± 0.95	-2.06 ± 1.50	-1.67 ± 1.06	0.0115*	(1, 2) < (2, 3)
Lower lip to E line	-4.02 ± 1.83	-2.15 ± 2.42	-2.75 ± 1.29	0.0268*	(1, 3) < (2, 3)
Skeletal					
SN-PP	-0.02 ± 0.55	0.03 ± 0.44	0.07 ± 0.44	0.8828	
SN-Occ	-0.32 ± 2.38	-0.63 ± 2.58	-3.02 ± 2.56	0.0089*	3 < (1, 2)
SN-Mn	0.26 ± 1.40	-0.15 ± 1.29	-0.40 ± 1.51	0.4247	
PTV-A	-2.32 ± 2.35	-1.22 ± 1.19	-1.57 ± 2.66	0.3608	
PTV-B	-0.58 ± 2.00	-1.07 ± 1.90	0.01 ± 2.52	0.3975	
ANS-Me	0.09 ± 3.09	0.73 ± 2.13	-0.86 ± 1.40	0.1825	
Dental angular					
SN-U1	-10.65 ± 5.17	-4.34 ± 5.77	-1.25 ± 2.68	0.0000***	1 < (2, 3)
SN-C	-7.88 ± 6.48	-2.29 ± 5.80	-2.35 ± 3.62	0.0081*	1 < (2, 3)
SN-U6	0.71 ± 2.93	-0.10 ± 4.63	0.03 ± 2.80	0.7920	
MP-L1	-12.99 ± 6.37	-8.73 ± 7.81	-8.15 ± 6.70	0.1180	
MP-L6	-1.98 ± 6.64	-4.84 ± 5.65	-2.72 ± 5.13	0.3811	
Dental linear					
PTV-U1	-7.06 ± 2.25	-5.79 ± 2.56	-5.63 ± 1.45	0.1337	
PTV-C	-6.24 ± 2.60	-5.47 ± 2.19	-5.51 ± 2.01	0.5786	
PTV-U6	0.06 ± 1.51	0.25 ± 1.16	0.51 ± 1.43	0.6701	
PP-U1	-1.18 ± 2.04	-1.47 ± 1.06	-3.76 ± 1.02	0.0000***	3 < (1, 2)
PP-C	-1.41 ± 1.37	-2.08 ± 1.27	-3.43 ± 1.21	0.0003**	3 < (1, 2)
PP-U6	-0.13 ± 1.51	-0.38 ± 1.16	-0.39 ± 0.91	0.7889	
LC-L6	-0.71 ± 1.90	-1.19 ± 1.28	-1.73 ± 1.39	0.1965	
MP-L1v	-1.08 ± 1.56	-0.78 ± 1.22	-1.04 ± 1.19	0.8030	
MP-L6v	0.03 ± 1.63	0.24 ± 1.25	0.14 ± 0.97	0.9075	

Values are presented as mean ± standard deviation.

Group 1, The C-lingual retractor group; group 2, the antero-posterior lingual retractor with parallel tube group; group 3, the antero-posterior lingual retractor with distally tipped tube group.

* $p < 0.05$, ** $p < 0.01$, and *** $p < 0.001$; based on one-way variable analysis of three groups.

The abbreviations of the variables are described in Table 3.

Refer Table 2 for definitions of the landmarks.

may reinforce the counterclockwise movement of the anterior segment by directing the guided bar along the path hole.

Because of the limitation of the retrospective design in the study, there were differences between the groups in the initial overbite and occlusal plane steepness. The patients in group 3 had greater intrusion of the anterior teeth to achieve the ideal overbite and overjet, compared to the other groups.

The angulation or position of the posterior teeth in each group did not change significantly during the *en masse* retraction. The minor vertical and horizontal

changes of the posterior teeth in the group 1 could be associated with the movement and settling of the mandibular teeth. Group 2 (i.e., the group with the parallel tube) had a tendency for mesial molar tipping because of the directional vector of miniscrews and lever arms. In group 3, we expected to see the molars tip posteriorly during retraction because of friction in the distally tipped tubes; however, the changes were insignificant.

The likely reason for the insignificant changes of the posterior dentition in the APLR groups could be that the enhanced anchor preparation was associated with the

splinting of the posterior dentition by buccal meshes. The clockwise moment of the anterior segment during retraction would cause the rigid guided bar to lift the posterior segment upward, which may contribute to preventing the extrusion of the molars.

When no anchor loss is desired during APLR application, close monitoring is essential. If the patient could also benefit from posterior intrusion, the transpalatal arch could be connected with traction to the palatal TSAD anchors. Finite element analysis could be used to determine the ideal application of forces to produce the movements for the best outcome. The clinician could predict the correct lever arm location and length so that the force vector is properly correlated with the center of resistance.^{5,16} The location of the lever arm and tube, and tube angulation can be designed for each patient's problem list using the three-dimensional-computer-aided design/computer-aided manufacturing method.¹⁰ An adjustment of the tube position affects the amount of intrusion, independent of the height difference between the lever arm and the TSAD. To learn more about planning the three-dimensional effects of anterior segment retraction and positional change of point-A requires further cone-beam computed tomography research. We believe the force system in this technique is quite complex, and the exact biomechanics that produce the desired outcome require further study.

CONCLUSION

A comparison of the CLR and APLR systems confirmed that adding posterior segmental control units (e.g., mesh splint, tube, and guide wire) produced more efficient and effective retraction, better torque control, and vertical changes in the anterior dental segment. Tipping the posterior tube distally significantly increased the amount of intrusion of the anterior segment. This system facilitated three-dimensional control of the bodily retraction, intrusion, and torque control. This approach could become an alternative treatment modality for lingual retraction.

ACKNOWLEDGEMENTS

The authors wish to give special thanks to Professor Kyu-Rhim Chung, Chairman of the Department of Orthodontics at the School of Medicine of Ajou University (Suwon, Korea), for providing supporting research data and valuable comments during manuscript preparation. The antero-posterior lingual retractor system was derived from the C-lingual retractor, which was developed by Professor Chung.

REFERENCES

- Hong RK, Heo JM, Ha YK. Lever-arm and mini-implant system for anterior torque control during retraction in lingual orthodontic treatment. *Angle Orthod* 2005;75:129-41.
- Lee EH, Yu HS, Lee KJ, Park YC. Three dimensional finite element analysis of continuous and segmented arches with use of orthodontic miniscrews. *Korean J Orthod* 2011;41:237-54.
- Jeong GM, Sung SJ, Lee KJ, Chun YS, Mo SS. Finite-element investigation of the center of resistance of the maxillary dentition. *Korean J Orthod* 2009;39:83-94.
- Chung KR, Oh MY, Ko SJ. Corticotomy-assisted orthodontics. *J Clin Orthod* 2001;35:331-9.
- Mo SS, Kim SH, Sung SJ, Chung KR, Chun YS, Kook YA, et al. Torque control during lingual anterior retraction without posterior appliances. *Korean J Orthod* 2013;43:3-14.
- Chung KR, Kook YA, Kim SH, Mo SS, Jung JA. Class II malocclusion treated by combining a lingual retractor and a palatal plate. *Am J Orthod Dentofacial Orthop* 2008;133:112-23.
- Nelson G, Ahn HW, Jeong SH, Kim JS, Kim SH, Chung KR. Three-dimensional retraction of anterior teeth with orthodontic miniplates in patients with temporomandibular disorder. *Am J Orthod Dentofacial Orthop* 2012;142:720-6.
- Kim JS, Kim SH, Kook YA, Chung KR, Nelson G. Analysis of lingual en masse retraction combining a C-lingual retractor and a palatal plate. *Angle Orthod* 2011;81:662-9.
- Kwon SY, Kim Y, Ahn HW, Kim KB, Chung KR, Kim Sunny SH. Computer-aided designing and manufacturing of lingual fixed orthodontic appliance using 2D/3D registration software and rapid prototyping. *Int J Dent* 2014;2014:164164.
- Kwon SY, Ahn HW, Kim SH, Park YG, Chung KR, Paik CH, et al. Antero-posterior lingual sliding retraction system for orthodontic correction of hyperdivergent Class II protrusion. *Head Face Med* 2014;10:22.
- Kim SH, Hwang YS, Ferreira A, Chung KR. Analysis of temporary skeletal anchorage devices used for en-masse retraction: a preliminary study. *Am J Orthod Dentofacial Orthop* 2009;136:268-76.
- Jee JH, Ahn HW, Seo KW, Kim SH, Kook YA, Chung KR, et al. En-masse retraction with a preformed nickel-titanium and stainless steel archwire assembly and temporary skeletal anchorage devices without posterior bonding. *Korean J Orthod* 2014;44:236-45.
- Melsen B. Biological reaction of alveolar bone to orthodontic tooth movement. *Angle Orthod* 1999;

- 69:151-8.
14. Ahn HW, Moon SC, Baek SH. Morphometric evaluation of changes in the alveolar bone and roots of the maxillary anterior teeth before and after en masse retraction using cone-beam computed tomography. *Angle Orthod* 2013;83:212-21.
 15. Park JH, Tai K, Takagi M, Miyajima K, Kojima Y, Joo BH. Esthetic orthodontic treatment with a double J retractor and temporary anchorage devices. *Am J Orthod Dentofacial Orthop* 2012;141:796-805.
 16. Hong RK, Lim SM, Heo JM, Baek SH. Orthodontic treatment of gummy smile by maxillary total intrusion with a midpalatal absolute anchorage system. *Korean J Orthod* 2013;43:147-58.